



Published by DiscoverSys

# Ozonated aloe vera oil improve wound healing by decreasing neutrophil count and wound diameter in *Sprague dawley* rats with full-thickness skin defect



Rezah Vahlepi<sup>1</sup>, Muhammad Thohar Arifin<sup>1,2\*</sup>, Muhammad Nur<sup>3</sup>,  
Muflihatul Muniroh<sup>1,4</sup>, Neni Susilaningsih<sup>1,5</sup>

## ABSTRACT

**Introduction:** Wounds fatality is possible on instances where treatment is not conducted correctly. Moreover, Aloe Vera possesses anti-microbial activities, while ozone has bactericidal and antioxidant effects. This study is, therefore, aimed at assessing the number of neutrophils and the diameter of full-thickness wounds, following the multilevel dose administration of ozonated aloe vera oil.

**Methods:** This is an experimental study, based on a post-test only control group design, with treatment and control groups. A total of 50 Sprague Dawley rats (250 ± 50 grams) were randomly divided into 10 units, the control was administered aloe vera oil, gentamicin ointment, and the treatment with ozonated aloe vera oil at varied dose of 600, 1200, and 1800 mg/ml. Subsequently, five groups

were terminated on the 3rd day, while the remaining groups were euthanized on the 7th day. The neutrophil counts were obtained after histological examination with Hematoxylin Eosin (HE) stain, while the wound diameter was measured using calipers.

**Results:** There were significant differences between the control and treatment groups. This was evidenced in the decreased neutrophil count after administering ozonated aloe vera oil at a dose of 1800 mg/ml, compared to 1200 and 600 mg/ml, and also aloe vera oil and gentamycin ointment. Furthermore, wound diameter was substantially reduced with all ozonated treatments, than the aloe vera oil and gentamycin treatments.

**Conclusion:** Ozonated aloe vera oil is characterized by the capacity to improve wound healing

**Keywords:** Full-thickness defect wound healing, Sprague Dawley, Ozonated aloe vera oil

**Cite this Article:** Vahlepi, R., Arifin, M.T., Nur, M., Munitorh, M., Susilaningsih, N. 2020. Ozonated aloe vera oil improve wound healing by decreasing neutrophil count and wound diameter in *Sprague dawley* rats with full-thickness skin defect. *IJBS* 14(2): 48-54. DOI: [10.15562/ijbs.v14i2.253](https://doi.org/10.15562/ijbs.v14i2.253)

## INTRODUCTION

The physiological response to skin injuries, through a process known as wound healing, consists of various complex pathways, required to restore tissue integrity, comprising blood clots formation, acute and chronic inflammatory responses, neovascularization, and cell proliferation to apoptosis. These activities are mediated by various cells, cytokines, matrices, and growth factors, through three phases, encompassing inflammatory, tissue proliferation, and remodeling. The Inflammation phase extends from the inception of injury to day 3. The process is characterized by vasoconstriction, followed by the collaborative activities of platelets and fibrinogen to form blood clots. The Neutrophil cells assemble to prevent bacterial infection, and then the keratinocytes.<sup>1-4</sup>

The results suggest Aloe vera accelerates wound healing by promoting the proliferation and migration of fibroblasts and keratinocytes and by protecting keratinocytes from preservative-induced death.<sup>5</sup>

Ozone (O<sub>3</sub>) is a oxidant much stronger than oxygen, with the ability to oxidize numerous substances that are inert to oxygen under normal conditions.<sup>6</sup> Some literature have confirmed the capacity to dissolve in plasma, water, serum, physiological saline and produce ROS (radical oxygen space). Moreover, the lipids present in plasma resemble those in lipoprotein, and thus undergo peroxidation, through an ozone dependent process. The H<sub>2</sub>O<sub>2</sub> produced is said to play an important role in biochemically and immunologically activating the body.<sup>7,8</sup>

Ozone is widely recognized as one of the best bactericidal, antiviral and antifungal agents. Currently, they have been empirically used as a chronic therapeutic mediator in chronic wounds, tropical and ischemic ulcers, resulting from the ability to decrease bacterial infections, heal dermal damage and increase oxygen pressure on exposure.<sup>9,10</sup>

Neutrophils are the first inflammatory cells translocated to the injury site, with the main role

<sup>1</sup>Biomedical Magister Program, Faculty of Medicine, Universitas Diponegoro, Semarang, Indonesia

<sup>2</sup>Neurosurgery Department, Faculty of Medicine, Universitas Diponegoro-Kariada General Hospital, Semarang, Indonesia

<sup>3</sup>Physic Division, Faculty of Science and Mathematics, Universitas Diponegoro, Semarang, Indonesia

<sup>4</sup>Anatomy and Histology Department, Faculty of Medicine, Universitas Diponegoro, Semarang, Indonesia

<sup>5</sup>Physiology Department, Faculty of Medicine, Universitas Diponegoro, Semarang, Indonesia

\*Corresponding to:  
Muhamad Thohar Arifin;  
Department of Neurosurgery,  
Faculty of Medicine, Universitas  
Diponegoro, Jl. Prof Soedarto  
Tembalang Indonesia;  
[thohar@fk.undip.ac.id](mailto:thohar@fk.undip.ac.id)

of defending the body against infections, and are drawn to the area within 24-36 hours after injury.<sup>11</sup> These cells are recruited in high numbers to phagocyte debris and microorganisms, including reactive oxygen species (ROS).<sup>12</sup> Also, they are a part of the inflammatory response, characterized by the ability to secrete inflammation strengthening signals at the early stages of healing, and also act as an indicator to terminate the process. Moreover, fibroblasts and myofibroblasts are mainly implicated in the elevation of wound size, by providing the contractile force needed to join both edges of the injury.<sup>13</sup> This study, therefore, aims to determine the effect of ozone in the form of ozonated aloe vera oil, in accelerating the wound healing time of full-thickness defect in ozone-treated Sprague Dawley mice. The evaluation was based on neutrophil count and the resulting wound diameter.

## MATERIAL AND METHODS

### Study design

This is an experimental research with post-test only control group design. The process involves a control, with standard therapy/intervention, and the treatment group. The outcome data were recorded after the duration of therapy. A total of ten groups were created, where the controls, P1 and P2 received aloe vera oil, and gentamicin, respectively for 3 days. Furthermore, P3, P4 and P5 were administered ozonated Aloe vera Oil at a dose of 600, 1200, and 1800 mg/ml of ozone, respectively for 3 days. Therefore, P6 and P7 groups were provided with aloe vera therapy and gentamicin, respectively for 7 days, while P8 P9 and P10 received ozonated Aloe vera Oil at a dose of 600 1200, and 1800 mg/ml ozone, respectively for 7 days. The measurements were conducted at the end of the intervention period in each group.

### Animal model

The sample of this study include 50 adult male Sprague Dawley rats, weighing  $250 \pm 50$  grams, distributed randomly into 10 groups, with 5 in

each. Also, a full-thickness defect measuring 1 cm in diameter was created on the back of the rat. The samples were maintained at room temperature of  $28.0 \pm 2.0^\circ\text{C}$ , and provided with 12 hours light, from 06.00-18.00 and darkness from 18.00-06.00. These conditions were to ensure the elimination of stress, and feeding was conducted ad libitum.

### Wound model, ozonated aloe vera extract, and histopathology examination

**Figure 1** shows the 1-centimeter full-thickness wound on the back of the rat. Moreover, ozonated ointment, derived from mixing ozone from the generators and aloe vera oil, was obtained from the Plasma Research Laboratory of Diponegoro University. Therefore, a magnetic stirrer was used to facilitate the mixture to be ready for use as a treatment material. This sample was then collected for testing with a spectrometer or dissolved ozone meter kit, while potassium iodide titration method is used to measure ozone levels in ozone-depleting oils.

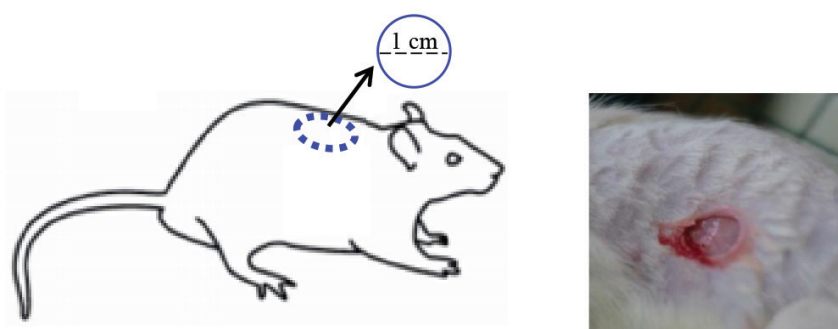
A total of 40 ml Aloe vera oil was used, with varied ozone concentrations of 600, 1200, and 1800 mg/ml. According to some literature, the minimum and maximum dose of ozone used was 700 and 1700 mg/ml, respectively. Meanwhile, magnetic stirrers are adopted to facilitate the mixing process, and the products were tested with a spectrometer or a dissolved ozone meter kit. At the end of the intervention (day 3 and 7), the wounded tissues were collected for histological examination. The procedure required the application of standard hematoxylin and eosin (HE) to determine the histological structure, while neutrophil count was assessed in 10 large fields of view.

### Statistical analysis

Data were analyzed using SPSS version 25.0 for windows (Chicago Illinois), and the numerical data were presented as mean and standard deviation or median, with an interquartile range. In addition, one Way ANOVA and alternative Non-Parametric Kruskal Wallis, followed by a Post-Hoc Test, were used to evaluate the differences between groups. Therefore, all values obtained were considered significant at  $p < 0.05$ .

## RESULT

A description of the number of neutrophils in each treatment group can be seen in (**Table 1**), neutrophil count in all group was normally distributed ( $p > 0.05$ ). **Table 2**, One Way ANOVA test results for neutrophil count obtained  $p$ -value  $< 0.05$ , Post Hoc Games-Howell test was performed to see a significant difference in the number of



**Figure 1.** Full-thickness wound in mice model

neutrophils between the two groups (Table 3). The results showed that the wound size diameter decreased significantly in the group treated with ozonated aloe vera oil with doses of 1200 mg/ml and 1800 mg/ml ozone (P4 and P5), if compared to the diameter of the wound size in the group receiving aloe vera oil therapy only (P1), with a

value of 77.60 mm; 85.40 mm versus 97.60 mm. The administration of ozonated aloe vera oil to each group of full-thickness defect tissue injury in Sprague Dawley rats showed its effect, which tended to reduce the size of the wound. It appears that by administering a specific dose of ozonated aloe vera oil (1200 mg/ml and 1800 mg/ml) the treatment groups P4 and P5, the reduction in wound size in the wound healing process compared with the administration of Ozonated aloe vera oil dose 600 mg/dl (P3) decreases significantly, with values of 77.60 mm and 85.40 mm (Table 4, Table 5).

The diameter of the wound in the P2 group (using gentamycin only) did not show a significant difference, with a value of 94.80 mm compared to the P1 and P3 groups. Still, there was no significant difference between the P4 and P5 groups. This shows that the administration of ozonated aloe vera oil has a substantial effect in increasing the healing response of full-thickness defect wounds which causes the wound size to shrink faster in Sprague Dawley rats (Table 5). There is a significant reduction in wound diameter in the group using ozonated aloe vera oil dose 1800 mg/ml (P10) when compared to the wound treatment group receiving aloe vera oil therapy alone (P6), with a value of 66.00 mm versus 79.00 mm. It appears that without the use of ozone, the diameter of the wound by giving aloe vera oil did not appear to be significantly different, with a value of 79.00 mm compared to 81.20 mm with the wound treatment group receiving gentamicin. The group that received ozone and aloe vera oil showed a significant reduction in wound size, with a value: 66.00 mm compared to 79.00 mm (Table 6 and 7). This indicates that administration of ozonated aloe vera oil significantly reduced the diameter of full-thickness defect wounds in the Sprague Dawley rat model. Tissue histology can be seen in figure 2, red arrow represent neutrophil.

**Table 1. Descriptive and normality tests of neutrophil counts in each group**

Study Group	Mean $\pm$ SD	Median (min-max)	p
P1	104.88 $\pm$ 16.28	109 (80.2 – 124)	0.813
P2	107.40 $\pm$ 9.97	102.6 (98.8 – 122)	0.265
P3	134.04 $\pm$ 12.19	126.8 (123.8 – 150.4)	0.122
P4	129.68 $\pm$ 17.40	127.4 (108.8 – 157.2)	0.325
P5	144.76 $\pm$ 23.16	140.4 (126 – 183.4)	0.169
P6	179.64 $\pm$ 43.70	192.4 (118.4 – 222.2)	0.533
P7	216.04 $\pm$ 72.18	179.2 (146.4 – 300.4)	0.137
P8	116.16 $\pm$ 8.49	112.4 (109 – 128.6)	0.258
P9	96.40 $\pm$ 10.06	93.4 (87.6 – 112.6)	0.337
P10	59.28 $\pm$ 8.68	59.2 (50.6 – 72)	0.632

**Table 2. One Way ANOVA test results for neutrophil count**

Study group	Mean $\pm$ SD	p
P1	104.88 $\pm$ 16.28	<0.001*
P2	107.40 $\pm$ 9.97	
P3	134.04 $\pm$ 12.19	
P4	129.68 $\pm$ 17.40	
P5	144.76 $\pm$ 23.16	
P6	179.64 $\pm$ 43.70	
P7	216.04 $\pm$ 72.18	
P8	116.16 $\pm$ 8.49	
P9	96.40 $\pm$ 10.06	
P10	59.28 $\pm$ 8.68	

**Table 3. Post Hoc Games-Howell test results for neutrophil count**

Study group	P2	P3	P4	P5	P6	P7	P8	P9	P10
P1	1.000	0.176	0.458	0.192	0.157	0.213	0.899	0.983	0.020*
P2	-	0.086	0.407	0.193	0.174	0.227	0.862	0.755	0.001*
P3		-	1.000	0.989	0.527	0.437	0.320	0.014*	<0.001*
P4			-	0.959	0.466	0.399	0.829	0.113	0.003*
P5				-	0.823	0.586	0.389	0.077	0.007*
P6					-	0.985	0.249	0.112	0.031*
P7						-	0.281	0.174	0.076
P8							-	0.142	<0.001*
P9								-	0.005*

\*Significant (p<0,05)

**Table 4. Kruskal Wallis-test result on wound diameter in groups P1-P5**

Study group	Median (min – max)	P
P1	96 (96 – 100)	0.002*
P2	96 (88 – 98)	
P3	96 (88 – 97)	
P4	87 (79 – 91)	
P5	77 (72 – 84)	

**Table 5. Mann Whitney test results of group P1-P5**

Study group	P2	P3	P4	P5
P1	0.238	0.432	0.008*	0.008*
P2	–	0.822	0.026*	0.008*
P3		–	0.027*	0.009*
P4			–	0.059

**Table 6. ANOVA test of wound diameter in group P6-P10**

Study group	Mean ± SD	p	Homogeneity test
P6	79.00 ± 6.52	0.003*	0.102**
P7	81.20 ± 5.22		
P8	73.00 ± 2.00		
P9	72.60 ± 6.95		
P10	66.00 ± 5.48		

**Table 7. Post-hoc test of wound diameter in groups P6-P10**

Study group	P7	P8	P9	P10
P6	0.535	0.101	0.081	0.001*
P7	–	0.029*	0.023*	<0.001*
P8		–	0.910	0.058
P9			–	0.073

## DISCUSSION

The results show a significant difference between the positive control and treatment groups. This is indicated by the positive effect of ozonated aloe vera oil on the number of neutrophils and the wound diameter in Sprague Dawley rats with full-thickness skin defect. The outcome is substantially prominent in the treatment group, compared to the samples treated with gentamicin, used as the positive control.

Neutrophils are part of the immune system, known to perform various functions during the normal wound repair process. These are

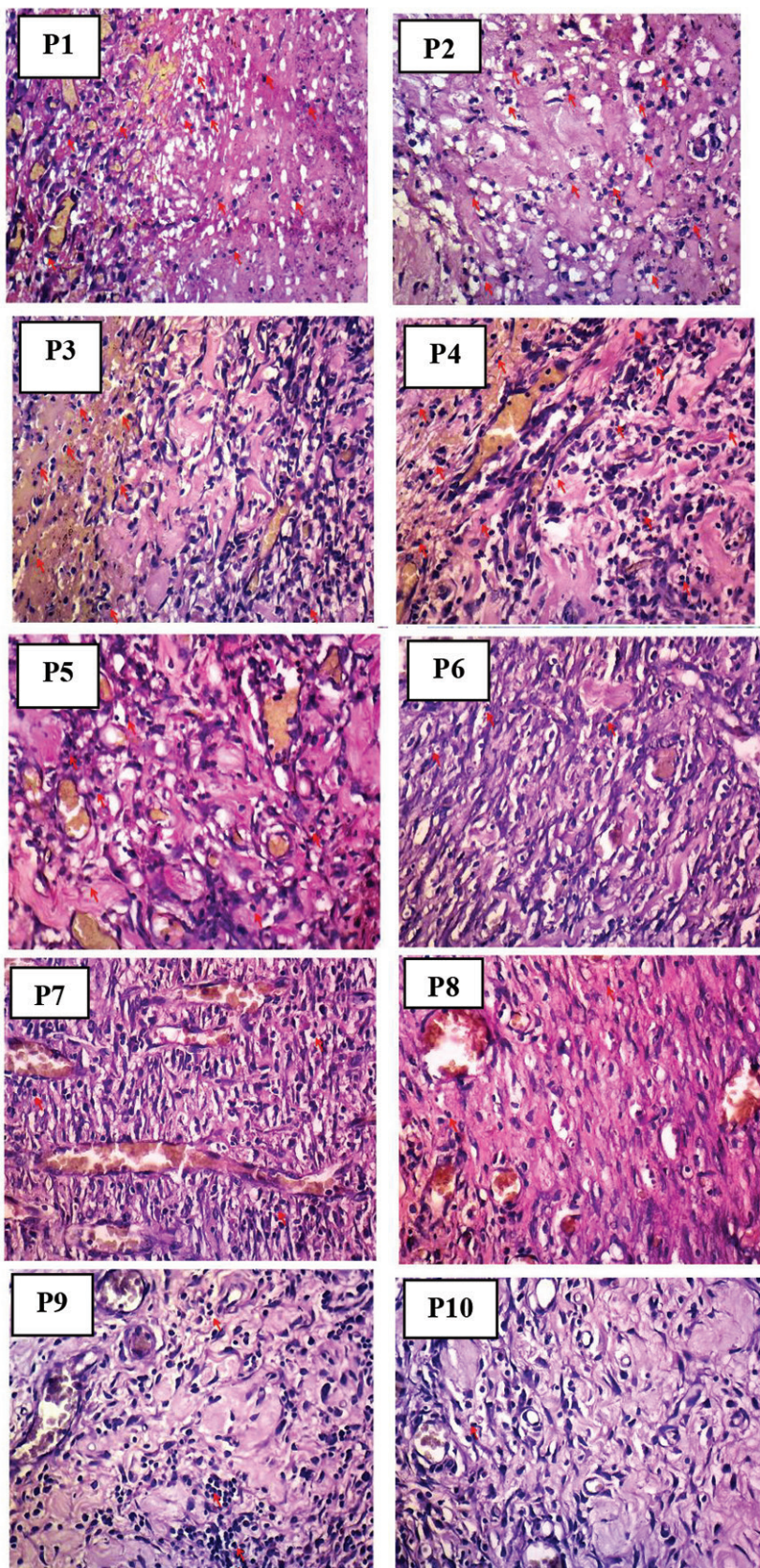
the first inflammatory cells translocated to the injury site, with the main role to defend the body against infections.<sup>11</sup> In addition, the arrival time is often within the first 24-36 hours, and they subsequently become the predominant cells in the initial inflammatory phase (48 hours after injury),<sup>14,15</sup> following the recruitment in high numbers. Moreover, neutrophils phagocytose debris and microorganisms to protect the body against infections, including against reactive oxygen species (ROS).<sup>12</sup>

The inflammatory response continues with the active recruitment of neutrophils in response to complement system activation, platelet degranulation, and degradation products from bacteria. These activities attract numerous inflammatory cytokines produced by activated platelets, endothelial cells, and degradation products of pathogenic agents. Therefore, neutrophils play an active role in tissue cleansing,<sup>16</sup> and also produce antimicrobial substances and proteases needed in the eradication and degradation of potential pathogens.

These cells are a part of the inflammatory response, characterized by the ability to secrete signals required to strengthen inflammation in the early healing stages, and also as an indicator for the phase termination. During normal wound healing, neutrophils undergo apoptosis after performing the expected function and are eventually swallowed by macrophages to provide the strong signals required to resolve the inflammation. This process is assumed to facilitate wound progression through the next healing phase. Therefore, the continued recruitment of active neutrophils and accumulation of apoptotic cells due to poor regulation of healing activities or reduced macrophage clearance causes prolonged inflammation and consequently contributes to the development of chronic wounds. In addition, phagocytic ability is applied to clean potentially pathogenic wounds, as the neutrophils help regulate inflammation and produce mediators needed to activate other important cells in the repair process.<sup>11</sup>

According to Travagli *et al.* ozone has the ability to heal wounds, due to the “oxidative killing” effect on organisms, including *Candida albicans* and *Staphylococcus aureus*. This activity reduces wound infections, controls contaminations similar to neutrophils, and reduces the time required for healing.<sup>17,18</sup> In addition, one of the theories underlying oxidative killing function involves the reaction between stable triozone and exudates at ulcer. This leads to decomposition into other water-soluble peroxides, followed by the production of hydrogen peroxide, subsequently increasing disinfection, and stimulation of ozone effects.





**Figure 2.** Histopathological picture showing the number of neutrophils using hematoxylin-eosin stain with a magnification of 100x; Group P1 - group P10.

Furthermore, ozone is also used as an antiseptic, based on the ability to inactivate bacteria, fungi, and protozoa, by interfering with the integrity of bacterial cell capsules, through the oxidation of phospholipids and lipoproteins. This is followed by penetration into the cell membrane, reaction with cytoplasm and causing changes to the cytoplasmic substances, including the conversion of closed circular DNA into open forms. Furthermore, there is also a possible decline in bacterial proliferation efficiency, as the penetrative ozone ability directly affects cytoplasmic integrity, and interferes with some levels of metabolic complexity.<sup>19</sup> The increase in oxygen tension at the injury site elevates granulation tissue formation, and consequently promotes the speed of wound closure.<sup>7</sup> Also, amplified expressions of TGF- $\beta$  and VEGF, known to play a role in the wound healing process, were reported in clinical and experimental researches with ozone therapy.

Various studies have proven the important role of ozone in wound healing and antimicrobial activities.<sup>7,20</sup> The antiseptic properties have been harnessed in the reduction of potential wound pathogens, therefore suppressing the number of neutrophils, terminating inflammation, and accelerating wound repair.

The results of data analysis show significant differences between groups treated with ozonated aloe vera oil at a dose of 1800 mg/ml, compared to 1200 and 600 mg/ml. This outcome was attributed to the substantial concentration-dependent oxidative killing role of ozone. In addition, various anti-oxidant systems are activated to defend the body against oxidation and the occurrence of ROS (Reactive Oxygen Species) in the form ( $O_3$ ,  $H_2O_2$ ,  $OH^+$ ), leading to the production of an antioxidant enzyme. These ROS act as secondary messengers for the various immunocyte and non-lymphoid cells involved in the wound repair process, and also play an essential role in adequate tissue repair and coordinating the recruitment of lymphoid cells to the injury site.<sup>10,11</sup>

Furthermore, ROS has the ability to regulate blood vessel formation (angiogenesis) at the wound site, thus promoting optimal blood perfusion, as well as the constriction (vasoconstriction) and relaxation (vasodilation).<sup>21</sup> During the wound healing process, platelets, macrophages, fibroblasts, endothelial cells and keratinocytes cells tend to use ROS and RNS as radicals in wound healing.

The effect of aloe vera on wound healing is possibly observed by assessing the number of neutrophils and estimating the wound diameter. In addition, the neutrophil count was performed on days 3 and 7 after treatment, using hematoxylin-



eosin staining, followed by calculation with a 100x magnification binocular microscope, featuring a square micrometer area of  $\mu\text{m}^2$ . Also, the reduction in wound size was calculated within a similar interval. The examination results show significant decline in neutrophil profiles and wound size shrinkage after administering aloe vera in each group of full-thickness skin defects, with or without ozonation, compared to the control, treated with gentamicin. This variation was due to the inflammation modulatory effect of Aloe vera, alongside the ability to improve wound closure diameter and promote new epithelialization. Also, the tropical variety has been exploited in various studies.

Wound diameter closure results from the influence of fibroblasts, the spindle-shaped cells originated from various tissues, especially the connective type.<sup>22</sup> This plays an essential role in wound healing by breaking down fibrin clots, forming new extracellular (ECM) matrices and collagen structures needed to support other cells for adequate wound healing.<sup>23</sup> Furthermore, fibroblasts also play a role in contracting/shrinking the injury size, while the subgroup termed myofibroblasts helps in contracting the site. The primary function of both cells are to provide the contractile force needed to join both edges of a wound.<sup>23</sup> This also causes shrinkage, characterized by the traction force instilled on the extracellular matrix, leading to ECM compaction, and consequently, wound closure.<sup>23</sup> Oryan *et al.* examined the 2x2 cm sized wound on the back of the rat treated with aloe vera gel, to investigate any possible improvements in the healing process. The results were evaluated based on wound surface parameters and size shrinkage, as well as epithelialization. Teplicki *et al.* also reported on improved healing, in terms of proliferation and migration of fibroblasts and keratinocytes, after using Aloe vera.<sup>22</sup> In addition, fibroblasts are required in ECM formation, which consequently plays an active role in wound closure, and the positive effect of Aloe vera is attained through increased cell migration, improved keratinocyte function, and epithelialization.<sup>24</sup>

The results showed the fastest healing in the group treated with ozonated aloe vera oil, at the largest dose of 1800 mg/ml, followed 1200 mg/ml, and 600 mg/ml, and then the positive control provided with gentamicin, as well as aloe vera oil, successively. Therefore, it is necessary to examine the effects of aloe vera oil by ascertaining the optimal dosage needed for wound healing.

The limitation of this study is the diversity in each rat hygiene, which is estimated to possibly influence the wound healing process. This makes it

difficult to determine the exact remediation phase on the third and seventh day of the sampling. In addition, the treatment course in Sprague Dawley rats is also possibly different from humans.

## CONCLUSION

Wound healing with the provision of ozonated aloe vera oil is improved in terms of neutrophil count and wound diameter. The effect substantially varies based on the dosage administered. However, the amount of neutrophil increased on day 3 and decreased on day 7, compared to the control groups treated with only gentamicin and aloe vera, respectively. In addition, ozonated aloe vera oil significantly influences the wound diameter of the full-thickness skin defect in Sprague Dawley rats, compared to the controls, and no significant variation was observed between the ozone doses of 1800 and 1200 mg/ml.

The limitation of this study is the diversity in each rat hygiene, which is estimated to possibly influence the wound healing process. This makes it difficult to determine the exact remediation phase on the third and seventh day of the sampling. In addition, the treatment course in Sprague Dawley rats is also possibly different from humans.

## CONFLICT OF INTEREST

The author declares there is no conflict of interest regarding publication of the current study.

## FUNDING

This research was funded by Direktorat Riset dan Pengabdian Masyarakat, Deputy Bidang Penguatan Riset dan Pengembangan Kementerian Riset dan Teknologi/Badan Riset dan Inovasi Nasional No 225-31/UN7.6.1/PP/2020.

## ETHICAL STATEMENT

This research was approved and declared ethically feasible by the Ethics Commission of the Public Health Faculty, Diponegoro University Semarang with ethical clearance number 132?EC/H/KEPK/FK-UNDIP/X/2019. All efforts were made to ameliorate harm to animals by administering anesthesia to all of the study animals before full-thickness wound model creation, keeping the animals in a well-maintained cage, and ensuring graceful termination of animals before we took tissue samples for histopathology examination.

## REFERENCES

1. Morison MJ. Practical guide on wound management. Ester M, Kurnianingsih S, editors. Jakarta: EGC; 2003. 1-9 p.

2. Sudjatmiko G. Practical guide on plastic reconstruction surgery. Kebajikan YK, editor. J: Mahameru Offset Printing; 2007. 1-8 p.
3. Sjahmuhidayat R, De Jong W. Text Book of Surgery 2<sup>nd</sup> edition. Sjahmuhidayat R, editor. Jakarta: EGC; 2004. 67-73 p.
4. Surgery Department, Indonesian University. Surgery Guide Module. Reksoprodjo S, editor. Jakarta: Binarupa Aksara Publisher; 2009. 387-8 p.
5. Teplicki E, Ma Q, Castillo DE, et al. The Effects of Aloe vera on Wound Healing in Cell Proliferation, Migration, and Viability. *Wounds*. 2018;30(9):263-268.
6. Peng-Hui W, Ben-Shian H, Huann-Cheng H, Chang-Ching Y, Yi-Jen C. Therapeutic effects of topical application of ozon on acute cutaneous wound healing. *J Korean Med Sci*. 2009;368-74.
7. Travagli V, Zanardi I, Valacchi G, Bocci V. Ozone and ozonated oils in skin diseases: a review. *Mediators Inflamm*. 2010;610418.
8. Saini R. Ozone therapy in dentistry: A strategic review. *J Nat Sci Biol Med*. 2011;2(2):151-3.
9. Valacchi G, Lim Y, Belmonte G, Miracco C, Zanardi I, Bocci V, et al. Ozonated sesame oil enhances cutaneous wound healing in SKH1 mice. *Wound Repair Regen*. 2011;19(1):107-15.
10. Campanati A, De Blasio S, Giuliano A, Ganzetti G, Giuliadori K, Pecora T, et al. Topical ozonated oil versus hyaluronic gel for the treatment of partial- to full-thickness second-degree burns: A prospective, comparative, single-blind, non-randomised, controlled clinical trial. *Burns*. 2013;39(6):1178-83.
11. Wilgus TA, Roy S, McDaniel JC. Neutrophils and Wound Repair: Positive Actions and Negative Reactions. *Adv Wound Care (New Rochelle)*. 2013;2(7):379-88.
12. Shaw TJ, Martin P. Wound repair at a glance. *J Cell Sci*. 2009;122:3209-13.
13. Bainbridge P. Wound healing and the role of fibroblast. *J Wound care [Internet]*. magonlinelibrary.com. 2013;25:18-25.
14. Gurtner GC, Werner S, Barrandon Y, Longaker MT. Wound repair and regeneration. *Nature*. 2008;453(7193):314-21.
15. Borges GÁ, Elias ST, da Silva SMM, Magalhães PO, Macedo SB, Ribeiro APD, et al. In vitro evaluation of wound healing and antimicrobial potential of ozone therapy. *J Cranio-Maxillofacial Surg*. 2017;45(3):364-70.
16. Midwood KS, Williams LV, Schwarzbauer JE. Tissue repair and the dynamics of the extracellular matrix. *Int J Biochem Cell Biol*. 2004;36(6):1031-7.
17. Elvis AM, Ekta JS. Ozone therapy: A clinical review. *J Nat Sci Biol Med*. 2011;2(1):66-70.
18. Zhang J, Guan M, Xie C, Luo X, Zhang Q, Xue Y. Increased growth factors play a role in wound healing promoted by noninvasive oxygen-ozone therapy in diabetic patients with foot ulcers. *Oxid Med Cell Longev*. 2014;2014:273745.
19. Pastar I, Stojadinovic O, Yin NC, Ramirez H, Nusbaum AG, Sawaya A, et al. Epithelialization in Wound Healing: A Comprehensive Review. *Adv Wound Care*. 2014;3(7):445-464.
20. Segá A, Zanardi I, Chiasserini L, Gabbriellini A, Bocci V, Travagli V. Properties of sesame oil by detailed <sup>1</sup>H and <sup>13</sup>C NMR assignments before and after ozonation and their correlation with iodine value, peroxide value, and viscosity measurements. *Chem Phys Lipids*. 2010;163(2):148-56.
21. Santoro MM, Gaudino G. Cellular and molecular facets of keratinocyte reepithelization during wound healing. 2005;304(1):274-86.
22. Teplicki E, Ma Q, Castillo DE, Zarei M, Hustad AP, Chen J, et al. The Effects of Aloe vera on Wound Healing in Cell Proliferation, Migration, and Viability. *Wounds a Compend Clin Res Pract*. 2018;30(9):263-8.
23. Atik N, Iwan ARJ. Comparison of Aloe vera L.) gel to povidone iodine in wound healing on mice model. *Maj Kedokt Bandung*. 2009;41(2):29-36.
24. Moriyama M, Kubo H, Nakajima Y, Goto A, Akaki J, Yoshida I, et al. Mechanism of Aloe vera gel on wound healing in human epidermis. *J Dermatol Sci*. 2016;84(1):e150-1.



This work is licensed under a Creative Commons Attribution